

Poultry Necropsy Basics

Edited by

Teresa Y. Morishita, DVM, PhD, Dipl ACPV

Poultry Veterinarian and Professor of Poultry Medicine & Safety

Why Would You Perform a Necropsy?

The necropsy (post-mortem dissection) of poultry is a procedure that can be utilized by the veterinarian, the manager, or the grower to find

scissors, a person can perform a basic necropsy to obtain diagnostic information; samples for further laboratory testing; or to ensure quality control of a flock. If you see a rise in mortality (number of dead birds) or a rise in morbidity (number of ill birds), the necropsy can provide you with more information about the disease, perhaps even a diagnosis. Your veterinarian and diagnostic laboratory can supply you with additional information on sampling techniques and shipping methods for diagnostic testing.

Getting Started

While walking through a poultry house, a recently dead or currently ill bird can be chosen for a necropsy. Birds that have been dead for more than several hours are not recommended for diagnostic specimens since the natural decomposition process will create changes that may be confused with true pathological lesions. If a specimen cannot be necropsied immediately, it should be refrigerated until it can be performed within a day. If you choose to euthanize and necropsy a sick bird, first observe it for abnormal breathing patterns, abnormal posture, ruffling of feathers, and/or nasal or ocular discharge before euthanizing the bird.

Euthanasia

The bird can be humanely euthanized by several approved methods including cervical dislocation (breaking the neck); using a carbon

dioxide chamber; or injecting a euthanasia solution, such as a high dose of barbiturates into a vein or directly into the heart. The last two methods are for laboratory or clinical settings. Cervical dislocation is usually performed under field conditions.

Basic Necropsy Needs

- A flat hard surface in a well-lighted area
- Access to water, soap, and paper towels
- Knife or scissors
- Gloves

A face mask is also recommended.

Performing a Necropsy

4. Tent the skin over the abdomen and cut with scissors or knife
5. Remove the skin overlying the abdomen and breast (from neck to cloaca).
6. Examine the breast muscle for decreased muscle mass, paleness (anemia), or bruising. Examine the keel bone. A crooked keel bone can indicate rickets (Fig. A).
7. Incise the abdominal muscle and cut through the ribs on the sides of the keel bone, cutting towards the joint where the wing is attached to the body.
8. Grasp the keel near the abdomen and pull upwards to expose the internal organs and chest cavity.
9. Examine the liver for changes in size or discoloration, white or yellow spots, abscesses, and/or tumors (Fig. B).

Figure B: The keel is lifted and the liver is visualized. The normal liver should not extend beyond the tip of the keel

10. Examine the air sacs for increased thickness and increased cloudiness. The normal air sac surfaces look like soap bubbles or clear cellophane wrap.
11. Cut the gastrointestinal (GI) tract between the esophagus and

nerves should be the same size bilaterally with no swellings. Enlargement of this nerve in one leg can be an

25. With a sharp knife, cut through the stifle and hock joints, looking for yellow or white pus-like material, blood, or excess fluid. Joints should appear shiny and white with just a small amount of clear, sticky fluid inside.
26. To find the bursa of Fabricius, cut through the cloaca and look for a grape-like structure towards the rear of the bird. The older the bird, the smaller the bursa. The bursa diminishes in size as the bird reaches sexual maturity.
27. Cut the bursa in half. It should have wrinkles running parallel to each other on the surface and be cream colored in appearance. Note any discoloration or swelling
28. Now return to the GI tract and starting with the proventriculus (Fig. B), cut length-wise. The inside wall is bumpy and this is normal as these are the digestive glands

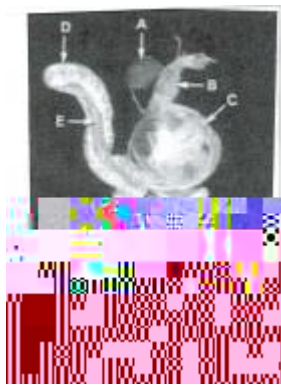


Figure C: The GI tract has been excised and positioned for further examination of the digestive organs:

- A=spleen
- B=proventriculus
- C=ventriculus
- D=duodenum
- E=pancreas
- F=Jejunum

29. Cut through the ventriculus, intestines, and ceca. Note the appearance of the inside walls (mucosa) and the presence of parasites (worms); blood; and/or a thickened or discolored surface.
30. Dispose of the carcass properly and disinfect surfaces and tools

Further Information

Contact your veterinarian for information on any other body parts (e.g., the brain or sinuses) you would like to examine or for information on sampling of organs for additional bacterial and viral testing.

Is Performing a Necropsy For Everyone?

A necropsy teaches you both normal and abnormal chicken anatomy. To learn as much as you can about your bird, it is always good to be skilled at performing a necropsy. If you have an occasional dead bird, you can examine it and possibly get clues as to why it died. However, if you have birds showing signs of disease or there are multiple deaths in your flocks, the best advice is to send your birds to a diagnostic laboratory to get an accurate diagnosis so you can institute a treatment and prevent the disease reoccurrence in your flock.